Introduction to Ultrasound

Joshua A. Copel, MD
Gottesfeld-Hohler Memorial Foundation
Resident Ultrasound Course Series
Produced with the assistance of
CREOG, ISUOG, AIUM

Disclosures

- Consultant, Jubel LLC
- Medical Advisory Board, Nuvo Inc

Credits

- Some technical slides courtesy of Philips Ultrasound
- ISUOG Basic ultrasound course and Titia E. Cohen-Overbeek

What is ultrasound?

- High frequency sound waves used to image tissue
- In medical imaging, typically 2-10 MegaHertz (MHz), or cycles/sec
- Audible range up to ~10 KiloHertz

Types of Ultrasound

Therapeutic Ultrasound

- Used in physical therapy to heal injured tissue
- Very high intensity ultrasound waves which alter the tissue

Types of Ultrasound

Diagnostic Ultrasound

- Used to create an image from the reflection of the sound wave
- Low intensity sound waves which are not intended to harm or change the tissue

What do we image with ultrasound?

- Developing fetus
- Pelvic structures
  - Uterus, ovaries
- Heart
  - Structure and blood flow

Why do we use ultrasound?

- To look for abnormal tumors in various organs
- To evaluate blood flow within the body
- To evaluate the function of the heart
- To access fetal development
  - Growth
  - Structural development

Modes of Operation

- 2D/Greyscale
  - Black and white image formed by the reflection of sound waves within the body
- M-mode (M=motion)
  - A graphic representation of the motion of an organ over time
  - Used primarily in cardiology

Modes of Operation

- Pulsed and Continuous Wave Doppler
  - A graphic *and audible* representation of blood flow
  - Used to measure flow
- Color Doppler
  - Color (red and blue) used to represent the presence *and direction* of blood flow

Modes of Operation

- Color Power Angiography (CPA)
  - A single color is used to represent the presence of blood flow within a vessel
  - The *direction* of flow is not known with CPA

2D/Greyscale Imaging

Pulse-Echo Method

- Ultrasound scanhead produces “pulses” of ultrasound waves
- These waves travel within the body and interact with various organs
- The reflected waves return to the scanhead and are processed by the ultrasound machine
- An image which represents these reflections is formed on the monitor

Interactions of Ultrasound with Tissue

- Reflection
  - The ultrasound reflects off tissue and returns to the scanhead
  - The ultrasound image is formed from reflected echos

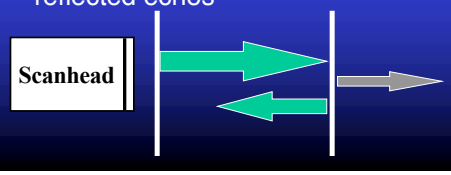

Interactions of Ultrasound with Tissue

- Transmission
  - Some of the ultrasound waves continue deeper into the body
  - These waves will reflect from deeper tissue structures

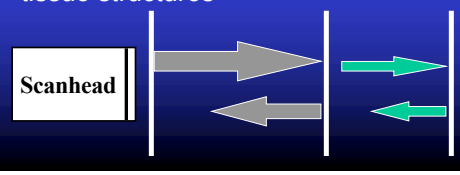

Interactions of Ultrasound with Tissue

- Attenuation
  - The deeper the wave travels in the body, the weaker it becomes

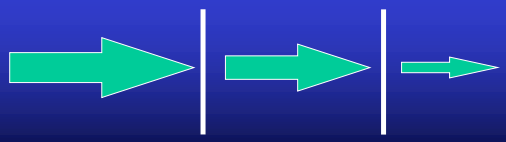

What determines how far the ultrasound wave can travel?

- The FREQUENCY of the scanhead
  - The HIGHER the frequency, the LESS it can penetrate
  - The LOWER the frequency, the DEEPER it can penetrate
- The frequency of a scanhead is labeled in MegaHertz (MHz)

What is a scanhead?

- Also called a *Transducer*
- Contains piezoelectric elements/crystals which produce the ultrasound pulses
- This element converts electrical energy into a mechanical ultrasound wave

Ultrasound transducer (probe)

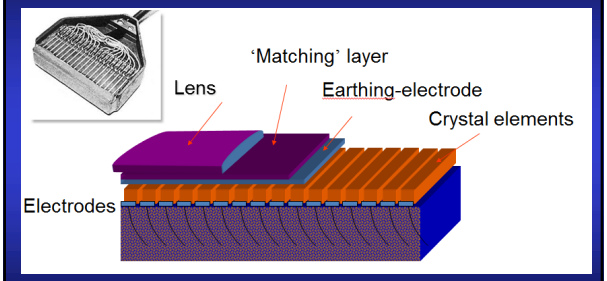



Microscopic view of scanhead

Frequency vs. Resolution

The frequency affects the QUALITY of the ultrasound image

- HIGHER frequency => BETTER resolution
- LOWER frequency => WORSE resolution

Frequency vs. Resolution

- A 10 MHz scanhead has very good resolution, but cannot penetrate very deep into the body
- A 3 MHz scanhead can penetrate deep into the body, but the resolution is not as good as the 10 MHz

Frequency Adjustment

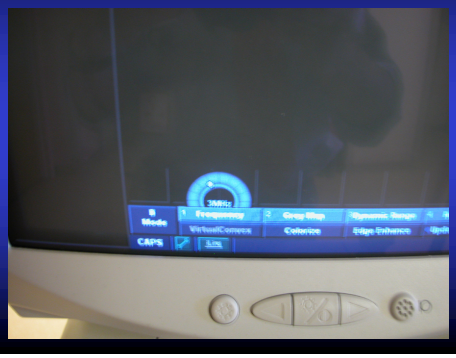

The Returning Echo

- Reflected echos return to the scanhead where the piezoelectric elements convert the ultrasound wave back into an electrical signal
- The electrical signal is then processed by the ultrasound system

How is the image formed on the monitor?

- The strength or amplitude or each reflected wave is represented by a dot
- The **position** of the dot represents the depth from which the returning echo was received
- The **brightness** of the dot represents the strength of the returning echo
- These dots are combined to form a complete image

Reflected Echos

- Strong Reflections = White dots
  - Diaphragm, gallstones, bone
- Weaker Reflections = Grey dots
  - Most solid organs, thick fluid
- No Reflections = Black dots
  - Fluid within a cyst, urine, blood

Image - resolution

- Lateral resolution ↔
- Axial resolution ↕
- Azimuthal resolution





What happens to the sound waves?

- Reflection
- Absorption
- Refraction
- Passage through the tissue

Acoustic output

- The "loudness" of the transmitted sound
- Measured in decibels (dB)
- Drops with square of distance through tissue
- Higher with focusing
- Responsible for bioeffects
- ALARA principle

Bioeffects

- Cavitation (gray-scale)
- Thermal (Doppler)
- MI & TI

Gain

- Properly "receive gain"
- Amplification of returning echoes
- Applied equally to signal & to noise
- Sometimes best image obtained by reducing overall gain

Gain

2D-gain

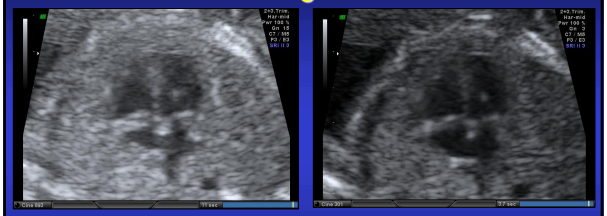

2D-gain

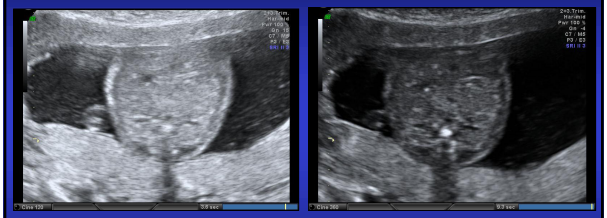

Time-Gain Compensation

- Sound travels through tissue at 1540 m/sec
- Gain can be adjusted for transit time, and therefore depth
- Can be used to adjust for attenuation as sound passes through tissue

Time-Gain compensation



Abdominal versus vaginal ultrasound

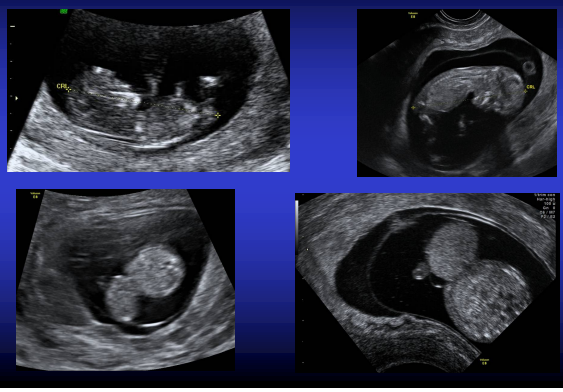

Getting the best image

- Ultrasound is reflected when a border between 2 different tissues is encountered
- Angle of insonation = angle of reflection

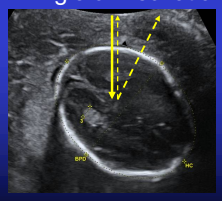
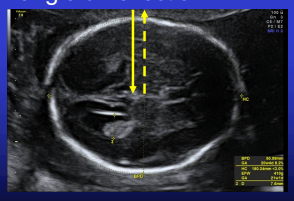

Depth + zoom


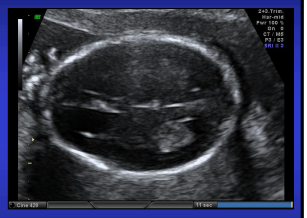

Focus

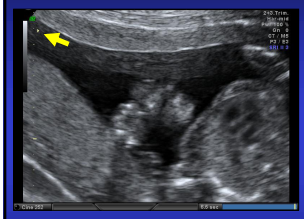
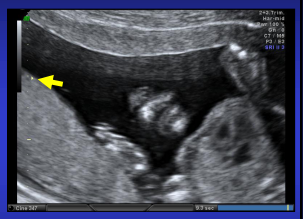

Presets

- Machine have "presets", adjustments optimized for various tasks, e.g.:
  - Fetal echo
  - Obstetrics
  - Gynecology
- Optimized for transducer frequencies, gain, focal zone, contrast
- Use them ! (and adjust them !)

Artifacts

- Wrong or misleading information caused by the ultrasound system or by interaction between ultrasound and tissues/organs.
- Phenomena on screen that do not reflect the real anatomy
  - Reverberations
  - Shadows

Reverberation

At the border of transducer and tissue the reflection is partly returned to the transducer surface and again transmitted to the tissue → new reflection → partly returned to the transducer surface etc.

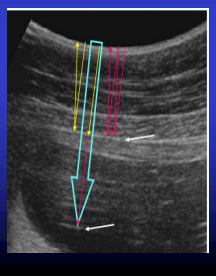

Shadow

Ultrasound waves can't pass strongly reflecting structures such as bone

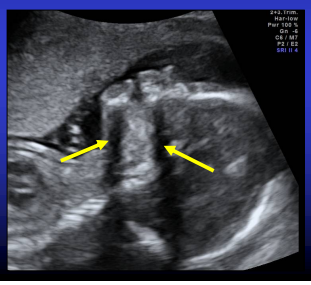

Image orientation

- Scan right hand, from right side of the patient
- Operate machine with left hand

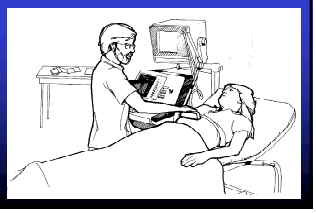

Image orientation

- Every transducer has a mark which you can feel and see
- Check the position of the transducer and the image on the monitor

Image orientation transverse

Rule:

When you look at your patient and at your monitor:

The **Right** side of the patient is **Left** on the monitor.

Use pressure of your finger to check the correct position

Fetus with its back to the left of the patient

NEVER rotate the transducer **>** 100 degrees. Go back to where you started

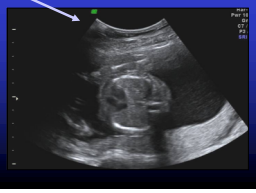

Image orientation transverse

The transducer is rotated 180 degrees and the fetus is lying with its back to the right side of the patient

Pressure from finger

Image orientation longitudinal

Rule:
When you look at your patient and at your monitor:
The **head** of the patient is **Left** on the monitor.

NEVER rotate the transducer **>** 100 degrees. Go back to where you started

Image orientation longitudinal

The transducer is rotated 180 degrees.

The fetus is now wrongfully diagnosed in a cephalic position

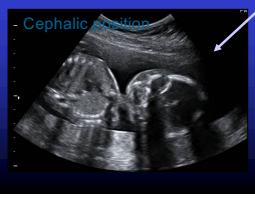

Pressure from finger

Care of equipment

- Clean transducer after every exam
- Disinfect vaginal transducer after every exam
- If you are not scanning make sure the transducer is in “Freeze” mode
- Don’t damage the cord between the transducer and the machine
- Don’t let the transducer fall
- Be careful when unplugging the machine

Resources

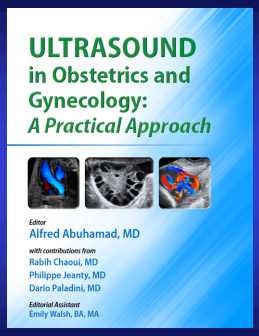

http://www.evms.edu/education/centers_institutes_departments/obstetrics_gynecology/ultrasound_ebook/

Resources