Deep Dive: Fetal brain

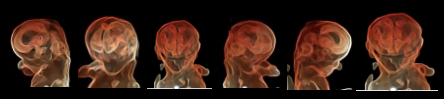

Ana Monteagudo, MD and Ilan E. Timor-Tritsch, MD

1

Introduction

- Many, find the brain anatomy challenging.
- It is true, that in order to understand what is seen in the ultrasound screen a profound understanding of the developmental embryology of the brain is necessary.
- In this lecture, will review the pertinent '*highlights*' of the brain embryology, but the main focus is the anatomy during the second trimester and beyond.

2

The Rhombencephalon- 7-9 weeks

Sonolucent structure, in the posterior region of the brain, measuring approximately 3-4 mm.

Marker of the ~8 weeks brain

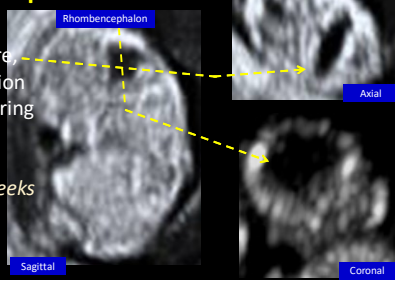

3

The Falx- After 9-10 weeks

- A midline structure that separates the single cavity of the forebrain into right and left hemispheres
- *Should be seen in all normal brains*
- *Marker of the ~ '10-week' brain*

4

The Normal Fetal Brain- 2nd & 3rd Trimesters

- 3 classic transabdominal (TAS) views using the axial
  - Transventricular
  - Transthalamic
  - Transcerebellar

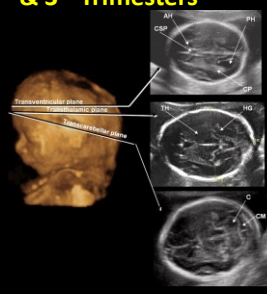

5

Transventricular plane

- Landmarks
  - Cavum septi pellucidi (1)
  - Frontal horns (2)
  - Choroid plexus (3)
  - Posterior horn (4)
  - Parieto-occipital fissure (POF)
  - Sylvian Fissure (SF)
- Measure LV

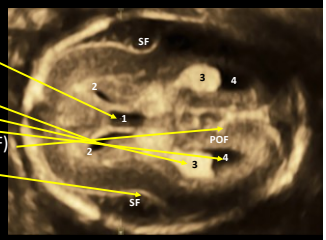

6

Transventricular plane
Where to Measure the Lateral Ventricle

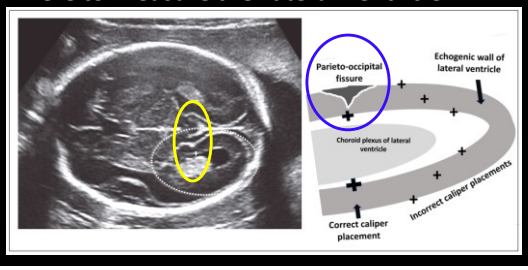

7

Transventricular plane
Asses for the Normal Shape of Lateral Ventricles

Back-to-back letters **'C'**

- Falx (4)
- Frontal horns (2)
- Choroid plexus (6)

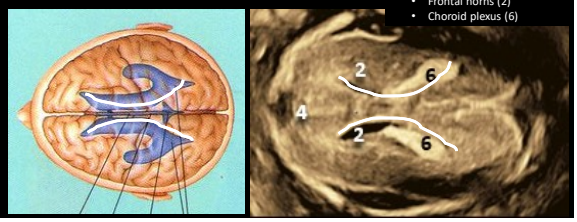

8

Transventricular plane
Asses for the Normal Sylvian Fissure aka Lateral Sulcus

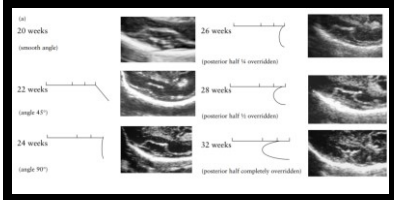

- With increasing GA; the fissure becomes more angular and deeper
- Abnormal S. fissure may be a marker of an underlying CNS anomaly

Diagram from Ultrasound Obstet Gynecol 2008; 32: 50–60

9

Transthalamic plane

- Landmarks
  - Cavum septi pellucidi (1)
  - Frontal horns (2)
  - Thalami (3)
  - Choroid plexus (6)
  - Posterior horn (7)
  - Sylvian Fissure (SF)
- Measure BPD and HC

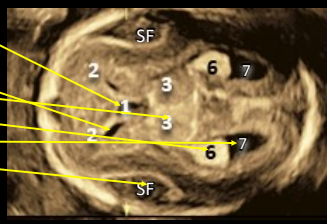

10

Transthalamic plane
Where to measure the BPD

Leading edge-to leading edge

- Transducer must be perpendicular & hemispheres and head should be symmetric.
- Calipers should be placed at the: outer edge of the near calvarial wall inner edge of the far calvarial wall
- *Orbits, ears or cerebellar hemispheres should not be in the plane*

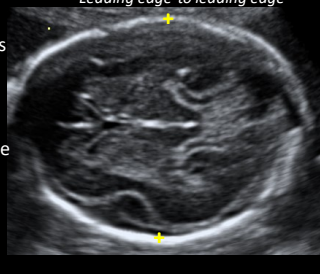

13

Transthalamic plane
Where to measure the HC

Around the outside of the skull bones

- Transducer must be perpendicular & hemispheres and head should be symmetric.
- Ellipse should be place around the outer table of the calvarium
- *Orbits, ears or cerebellar hemispheres should not be in the plane*

14

Transthalamic plane
Asses for the Normal Shape of Anterior Horns

Shaped like a "V"

- Upward & laterally diverging anterior horns

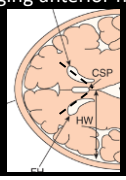

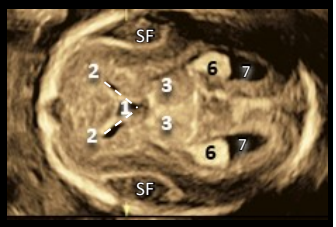

15

Transthalamic plane
Asses for the Normal CSP

- A fluid filled structure between the leaves of the septum pellucidum
- *If a central 'third-line' is seen this is NOT the cavum, but the fornix*

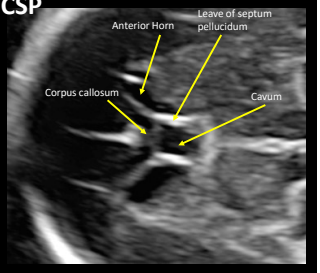

16

Transthalamic plane
What is the Fornix?

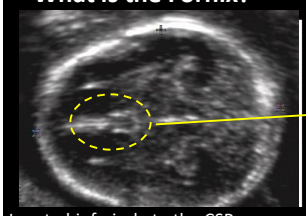

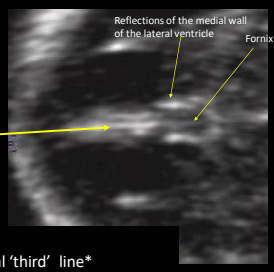

Located inferiorly to the CSP

- By US can be recognized as the central 'third' line*
- Another 'clue' the non-visualization of the frontal horns

*J Ultrasound Med 2008;27:25-31.

17

Transthalamic plane
Normal CSP and Fornix

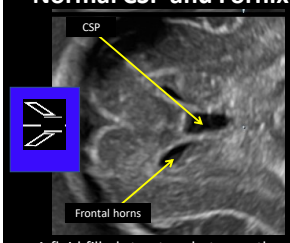

A fluid filled structure between the leaves of the septum pellucidum

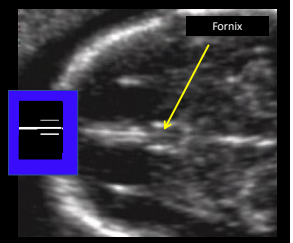

Fornix Central *'third-line'*
Non-visualization of the fluid filled FH

18

Transcerebellar plane

- Landmarks
  - Frontal horns (1)
  - Frontal lobes (4)
  - Cavum septi pellucidi (6)
  - Cerebellum (7)
  - Vermis (V)
  - Cisterna magna (8)
  - Cerebellar pedunculi (9)
  - Parietal lobes (10)
  - Sylvian fissure (SF)
- Measure the transcerebellar diameter and cisterna magna

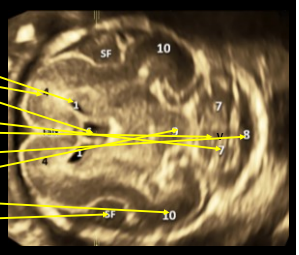

20

Transcerebellar plane
Where to measure the transcerebellar diameter (TCD)

- The TCD is measured at the widest part of the cerebellum, perpendicular to the falx
- *TCD in mm correlates with GA up to 20 weeks. After 20 weeks is larger than GA.*
- A TCD ≤ 2mm than the estimated GA or < 5% is a concerning finding.

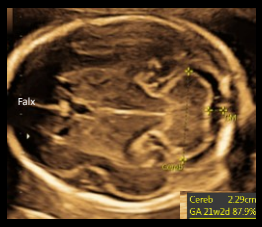

21

Transcerebellar plane
Where to measure the Cisterna Magna (CM)

- The CM is measured from the posterior margin of the vermis to the inside of the occipital bone in the midline.
- *Measurement of 2-10 mm is normal during 2nd to the 3rd trimesters.*

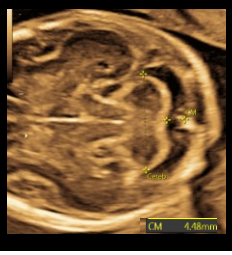

22

Transcerebellar plane

- Cerebellar hemispheres (1)
- Fourth ventricle (2)
- Vermis (3)
- Blake's pouch (4)
- Cisterna magna (5)

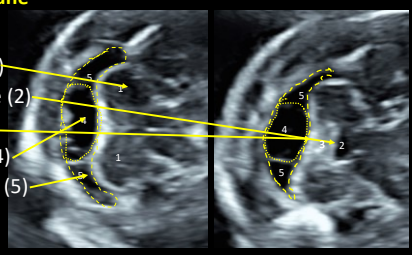

23

Transcerebellar plane
The Vermis < 20 weeks

"Absent -vermis"

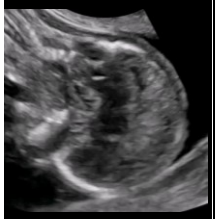

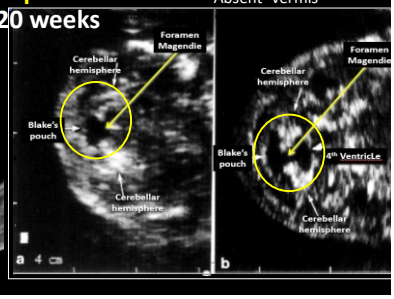

24

Transcerebellar plane
The Vermis < 20 weeks
The "Absent-Vermis"

If your scanning plane is too low… it can be confused with posterior fossa abnormality (abnormal vermis)

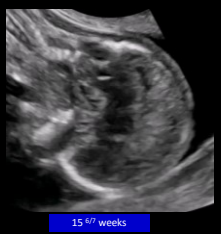

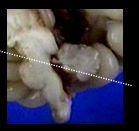

Normal

25

Transcerebellar plane
Cisterna Magna Septa

- Are NL anatomic structures; seen during the NL embryologic development of the posterior fossa.
- Usually, 2 septae, are imaged inferior & posterior from the vermis forming a cyst-like structure.
- Present in most fetuses (84-92%)
- *In actuality, they represent the walls of Blake's pouch*

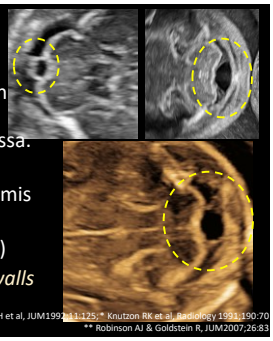

* Pretorius DH et al, JUM1992;11:125; * Knutzon RK et al, Radiology 1991;190:70
** Robinson AJ & Goldstein R, JUM2007;26:83

26

Transcerebellar plane
Blake's Pouch

- The cisterna magna septa are the walls of Blake's pouch
- Blake's pouch is a normal fingerlike appendage of the 4th ventricle.
- *'Potential marker' for normal development*

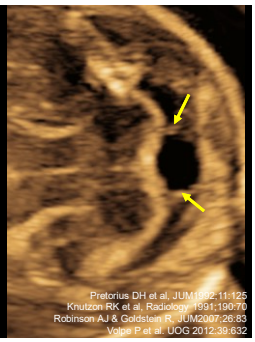

27

The Normal Fetal Brain- Beyond the Basics

- Coronal and median planes using TVS (or TAS)
- The anterior fontanelle provides an acoustic window resulting in high resolution and detailed images

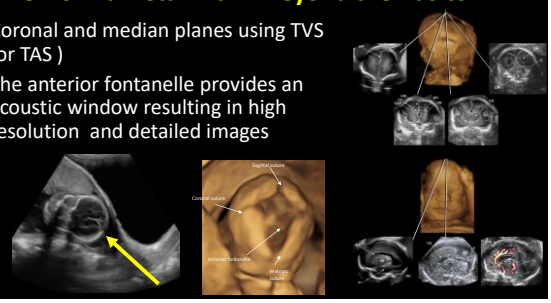

29

Coronal Plane

Tomographic coronal images of the fetal brain at 22 weeks results in multiple serial planes

Mid-Coronal

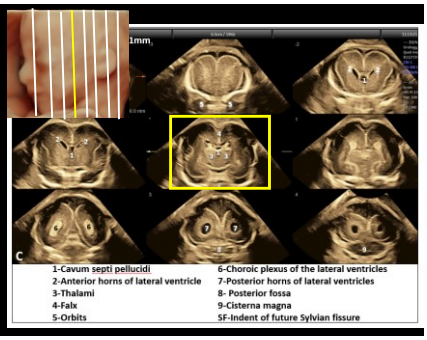

30

Mid-Coronal (or Transthalamic plane)

- Cavum septi pellucidi (1)
- Anterior horns (2)
- Thalami (3)
- Falx (4)
- Choroid plexus (5)
- Body of corpus callosum (6)
- Interventricular foramina (*)
- Sylvian fissure (SF)

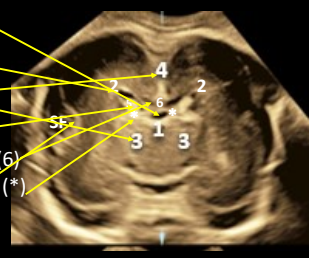

31

Mid-Coronal Plane
Falx Cerebri

- Midline
- Superior sagittal sinus
- Subarachnoid space
- Falx
- Interhemispheric fissure
- Body of the corpus callosum
- Cavum septi pellucidi

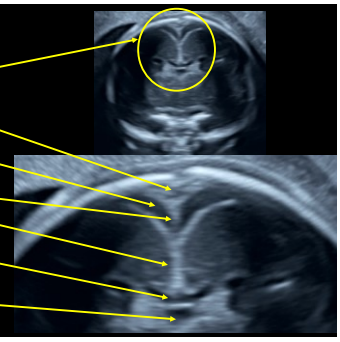

32

Mid-Coronal Plane
Interhemispheric Fissure

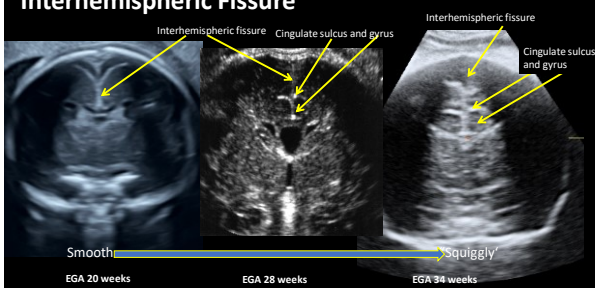

33

Mid-Coronal Plane
Cavum Septi Pellucidi

- A fluid filled structure between the sidewalls of the septum pellucidum

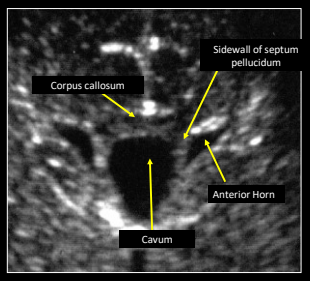

34

Mid-Coronal Plane
Anterior Horns

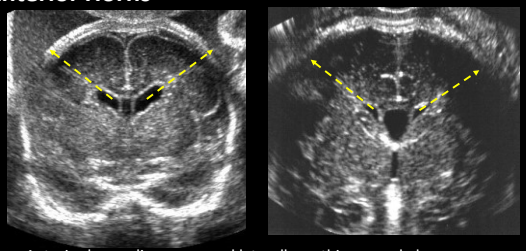

Anterior horns diverge up and laterally on this coronal plane

35

Mid-Coronal Plane
Third Ventricle

- Slit-like structure seen between the thalami
- *Typical width is about 1 mm up to 28 weeks; afterwards may enlarged to reach a width of 1.9 mm*
- If the width measures greater than 3.5 mm anytime during the pregnancy, it should be considered abnormal

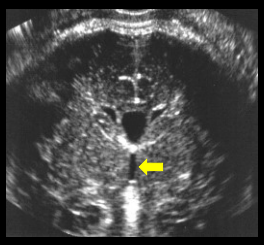

Radiology. 1997 Jun;203(3):641-4

36

Sagittal Median Plane

Tomographic coronal images of the fetal brain at 22 weeks results in multiple serial planes

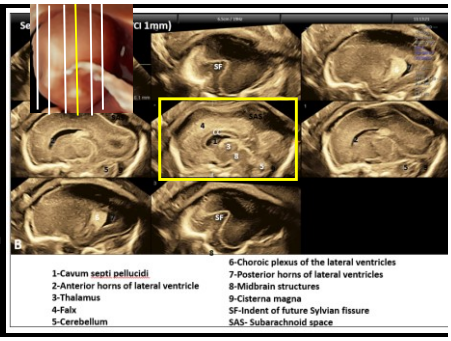

38

Sagittal Median Plane

- Corpus Callosum
- CSP (& Vergae)
- Thalamus (3rd ventricle)
- Tela chroidea
- Tectum (corpora quadrigemina)
- Posterior fossa
  - Cerebellar vermis
  - Cisterna magna
  - 4th ventricle
  - Fastigium

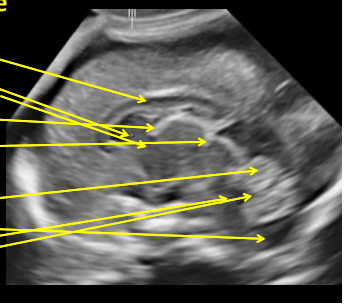

39

Median Plane
Corpus Callosum & Cavum Septi Pellucidi

Corpus Callosum
- Hypoechoic
- C-shaped

CSP
- Fluid filled space
- Develops together with the CC
- Continues posteriorly as the cavum vergae

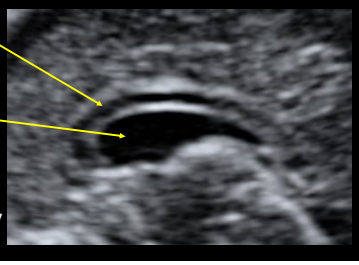

40

Corpus callosum & Cavum Septi Pellucidi

- The rostrum (beak), genu (knee), corpus (body) and the splenium (tail)
- Cavum septi pellucidi & vergae

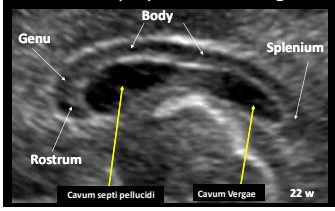

CC develops in a anterior to posterior fashion
Exception: Rostrum & anterior genu which develop last

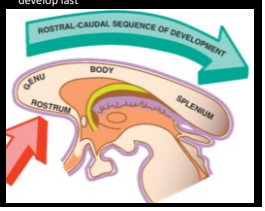

41

Median Plane
Corpus Callosum & Cavum Septi Pellucidi

- Splenium (tail) extends to quadrigeminal cistern (tectal plate)
  - If it doesn't this is suspicious for partial AGCC

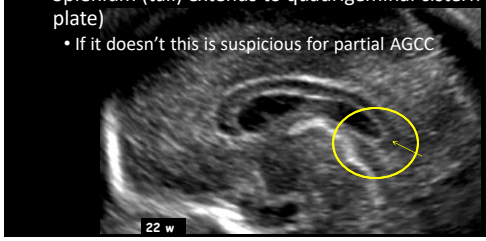

42

Median Plane
Nomograms Corpus Callosum

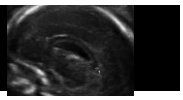

TABLE 1: Measurements of Corpus Callosum in Normal Prenatal Development

Gestational Age (weeks)	No. of Patients	Length (mm)	Thickness (mm)			C:B Ratio
			Genu	Body	Splenium	
19–19	5	16.9 ± 2.4	2.2 ± 0.5	1.3 ± 0.1	2.1 ± 0.1	0.290
20–21	5	20.6 ± 4.4	2.3 ± 0.6	1.6 ± 0.1	2.1 ± 0.9	0.352
22–23	5	23.3 ± 3.0	2.7 ± 0.6	1.7 ± 0.2	3.1 ± 0.2	0.343
24–25	7	29.8 ± 2.3	3.0 ± 0.6	1.9 ± 0.3	3.0 ± 0.3	0.362
26–27	8	33.7 ± 2.4	3.5 ± 0.6	2.0 ± 0.2	3.3 ± 0.6	0.393
28–29	11	25.8 ± 2.8	4.0 ± 0.7	2.0 ± 0.4	4.0 ± 0.8	0.386
30–31	7	36.8 ± 1.4	4.2 ± 0.5	2.1 ± 0.4	4.1 ± 0.7	0.356
32–33	11	39.1 ± 4.3	4.5 ± 1.2	2.5 ± 0.6	4.2 ± 0.8	0.379
34–35	10	40.6 ± 6.4	4.6 ± 0.5	2.5 ± 0.5	4.4 ± 0.6	0.370
36–37	12	41.9 ± 3.5	5.0 ± 0.4	2.5 ± 0.4	4.4 ± 1.3	0.387
38–39	12	43.0 ± 4.2	4.8 ± 0.7	2.6 ± 0.5	4.4 ± 0.6	0.386
40–42	8	44.0 ± 3.8	4.8 ± 0.4	2.6 ± 0.5	4.4 ± 0.7	0.379

Note.—Measurements are presented as mean ± 1 SD. The length of the corpus callosum was measured in 94 fetuses. thicknesses of the genu, body, and splenium were measured in 94, 95, 96 fetuses, respectively. C:B ratio = ratio of the lengt the corpus callosum to the anteroposterior diameter of the brain.

Malinger et al AJR 1993

Table 1. Fetal Corpus Callosum Length (mm) by GA

GA, wk+d	n	Mean	SD	95% CI
19+0–19+6	7	18.78	1.33	17.45–20.10
20+0–20+6	76	21.02	1.43	19.59–22.46
21+0–21+6	1002	23.20	1.54	21.66–24.74
22+0–22+6	1322	25.30	1.65	23.65–26.94
23+0–23+6	217	27.31	1.76	25.56–29.07
24+0–24+6	31	29.24	1.86	27.38–31.10
25+0–25+6	34	31.07	1.97	29.10–33.04
26+0–26+6	26	32.81	2.08	30.73–34.89
27+0–27+6	29	34.45	2.18	32.26–36.63
28+0–28+6	24	35.97	2.29	33.68–38.26
29+0–29+6	33	37.38	2.40	34.98–39.78
30+0–30+6	33	38.68	2.51	36.17–41.18
31+0–31+6	43	39.85	2.61	37.23–42.46
32+0–32+6	38	40.89	2.72	38.17–43.61
33+0–33+6	20	41.80	2.83	38.97–44.62
34+0–34+6	6	42.56	2.94	39.63–45.50
35+0–35+6	4	43.19	3.04	40.14–46.23
36+0–36+6	3	43.66	3.15	40.51–46.81
37+0–37+6	3	43.98	3.26	40.72–47.24

J Ultrasound Med 2014; 33:1065–1078

43

Median Plane
The tectal plate (Quadrigeminal Plate)

- It is the portion of the midbrain (tectum) upon which the superior and inferior colliculi sit.
- When fully formed, the tail of the corpus callosum reaches it
- Site for pathologies such as: Cysts, Lipomas

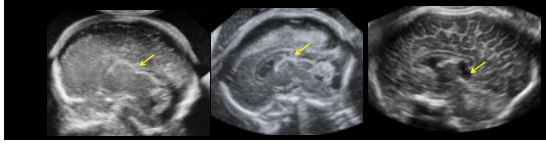

44

Median Plane
The tectal plate (Quadrigeminal Plate)

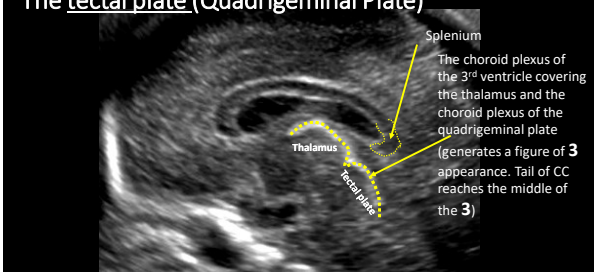

45

Median Plane
Gyri & Sulci

- Brain changes from smooth; to having multiple hyperechoic sulci
- Cingulate gyrus from about 24 weeks

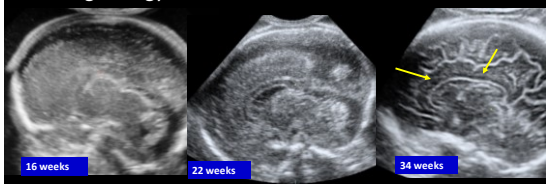

46

Median Plane
Gyri & Sulci- Adult-like appearance

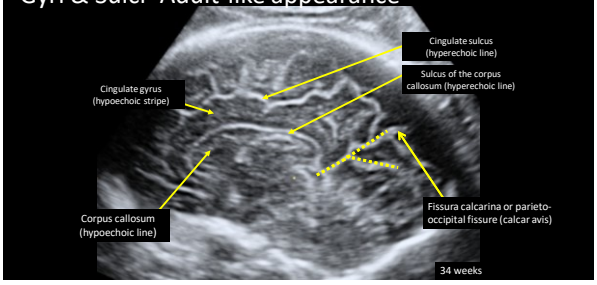

47

Median Plane
Gyri & Sulci- Adult-like appearance

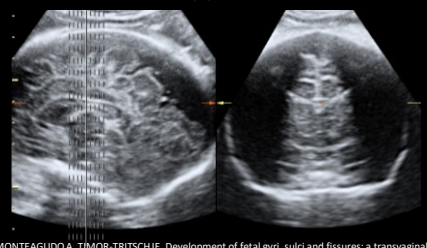

MONTEAGUDO A, TIMOR-TRITSCH IE. Development of fetal gyri, sulci and fissures: a transvaginal sonographic study. Ultrasound Obstet Gynecol 1997;9:222-8.

48

Median Plane
Corpus Callosum & Cavum Septi Pellucidi

- The development of corpus callosum is closely associated with that of the CSP
  - There cannot be a CSP without a covering corpus callosum
  - *However, a corpus callosum can be present in the absence of the CSP* such as in septal agenesis as the result of SOD

49

Median Plane
Corpus Callosum & Cavum Septi Pellucidi

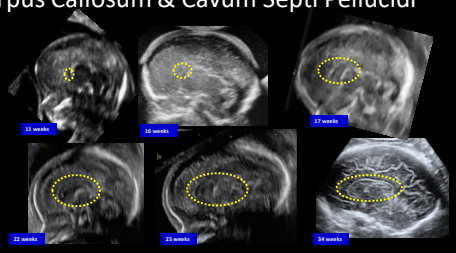

Best time to image is after 20 weeks

50

Median Plane
Corpus Callosum & Cavum Septi Pellucidi

- The CC reaches its final adult-like appearance at around the 28 wks.
- By the 3rd trimester the CSP begins to narrow in an occipital-to-rostral fashion; closure of the posterior part will occurs in most fetuses by term
- The cingulate sulcus is seen from 24-26 wks on

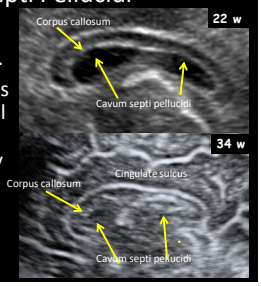

51

Median Plane
Arteries, Veins & Sinuses

- Best plane to image vessels that are in the midline
- Color/power Doppler reveals both the arterial and the venous system

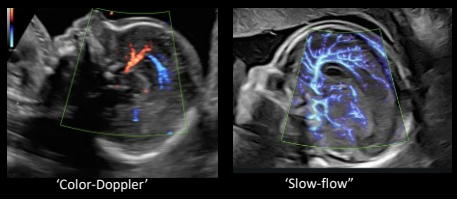

'Color-Doppler' 'Slow-flow"

52

Median Plane
Corpus Callosum & Pericallosal Arteries

- The presence of normal pericallosal arteries predicts normal development of the corpus callosum

53

Median Plane
Corpus Callosum & Pericallosal Arteries

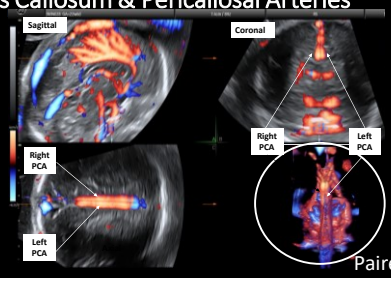

54

Median Plane
Corpus Callosum & Pericallosal Arteries

- Before 18 weeks, using only gray scale, the corpus callosum may not be evident.
- However, when using color Doppler if the pericallosal artery is present is proof that the CC is developing

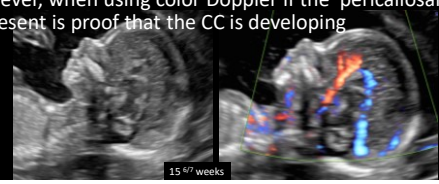

55

Median Plane
Pericallosal arteries at 11-13 weeks

- Several authors have demonstrated the presence of the pericallosal arteries in the 1st trimester using 2D and 3D Power Doppler
- It may be used to screen pregnancies at increased risk of AGCC

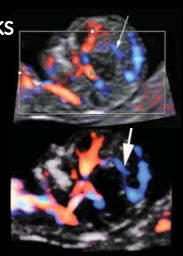

Pati M et al. J Ultrasound Med 2012;31:231–237. 7
Diaz-Guerrero L et al. Fetal Diagn Ther 2013; 34:85–89.
Conturso R et al. Fetal Diagn Ther 2015;37:305–309

56

Median Plane
Pericallosal arteries at < 18 weeks

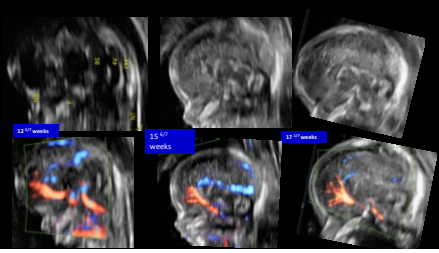

57

Median Plane
Pericallosal arteries at 12-25 weeks

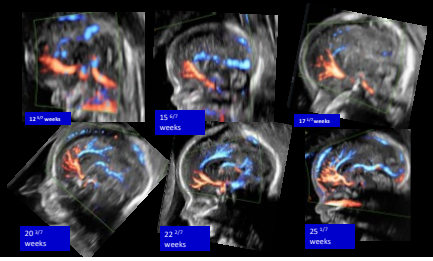

58

Median Plane
Beyond Pericallosal Arteries

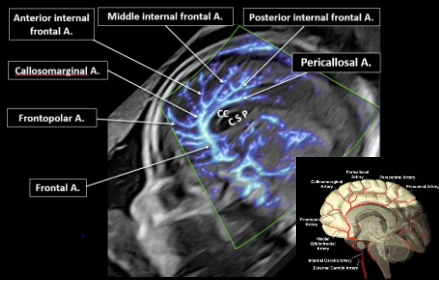

59

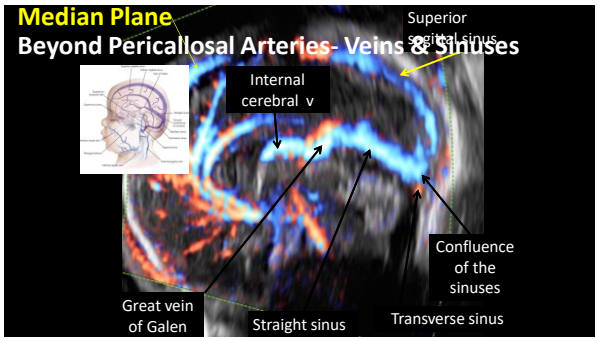

60

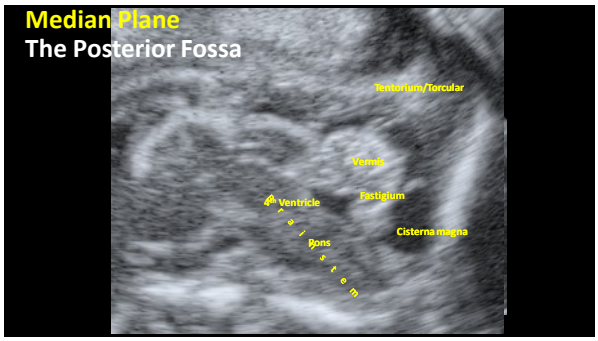

61

In Summary…….

- Becoming comfortable with the normal anatomy of the brain is the *key* to diagnose complex brain malformations.
- *Always start with the axial planes using TAS*

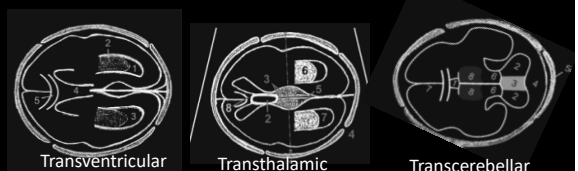

Drawings from Bethune, et al.AJUM August 2013 16 (3)

62

In Summary…….

- If an anomaly is suspected the next step is adding the coronal and sagittal planes; ideally obtained by TVS.
- *The mid-coronal and the median plane are the most valuable.*
- *Don't hesitate to add color Doppler*

63

64